

## Experience Using Tomosynthesis (T-smart) at Nara City Hospital



Mr. Takeshi Kuzuwa

Department of Radiology, Nara City Hospital

**Takeshi Kuzuwa, Mitsuaki Izumi, Syusaku Yoshimitsu, Mitsuru Ichihara**

Deputy Director, Director of Limb Trauma Center

**Hiroshi Yajima**

### 1. Introduction

Nara City Hospital (full name: Japan Association for Development of Community Medicine Nara City Hospital) was formed on December 1, 2004 when Nara Hospital (full name: National Hospital Organization Nara Hospital) was transferred to Nara City. Although Nara City Hospital was established by Nara City, the designated administrator of the hospital is in fact the Public Interest Incorporated Association, Japan Association for Development of Community Medicine, and is a publicly built and privately operated hospital. The new hospital was completed in December 2012 with the latest facilities and equipment, and medical practice commenced at the new hospital from January 2013. By increasing the number of surgical beds to 8, and establishing 8 new ICU beds and 10 new palliative care beds, the new hospital has created the means for providing advanced medical care. General emergency medical services are provided by specialists in emergency medical care who are based in the department of general medicine, forming a complete system of emergency medical care, while changes are underway to split the medical care department into separate centers of medical care for the provision of efficient and standardized medical services.

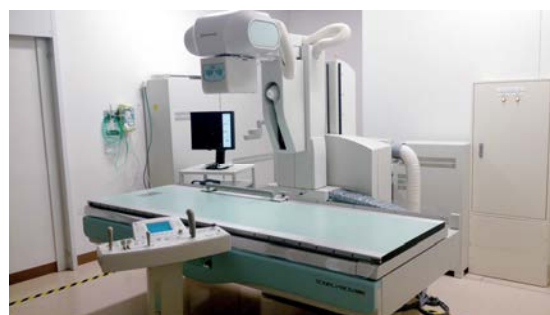As the core medical institution in Nara City, a city proud of its history and culture, and with 350 beds, Nara City Hospital aims to provide high-quality and efficient medical care with a smile and give all local residents peace of mind (Fig. 1).



**Fig. 1** External View of Nara City Hospital. Currently in Phase 2 of Construction Works. Scheduled for Completion by End of 2013

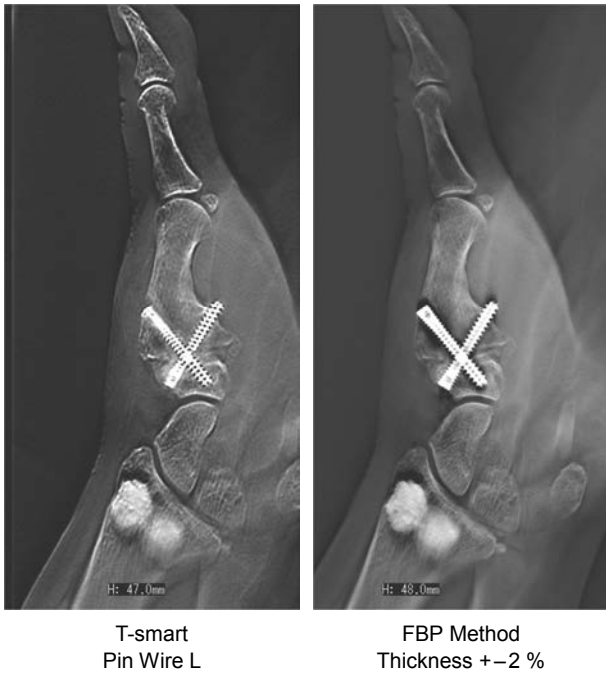
### 2. Current Situation at Nara City Hospital

The fluoroscopy system being used at our hospital is a SONIALVISION safire series (Fig. 2), which was introduced at the opening of the new hospital in January of 2013. The hospital has two R/F systems including one made by another manufacturer that is mainly used for cases related to the digestive system (endoscopy, etc.). The newly introduced SONIALVISION safire series is capable of tomosynthesis and slot radiography, and is mainly used for exams related to the bones and joints. Evolved from conventional tomography, tomosynthesis is able to provide multiple slices information from the data obtained from only a single exposure stroke by the reconstruction called FBP (Filter Back Projection) method which is commonly applied in CT scanner reconstruction. Thanks to its short operation times and efficiency of examinations, we effectively use this system in orthopedic surgery as a new examination tool. The newly introduced tomosynthesis also has a new tomographic image reconstruction function (hereafter, T-smart) that uses IR (Iterative Reconstruction) and is able to further reduce the presence of metal artifacts beyond what is possible with previous tomosynthesis. As shown in Fig. 3, T-smart reduces the undershoot that is visible around metal parts when using FBP, and also makes the image around the metal parts clearer.



**Fig. 2** SONIALVISION safire Series

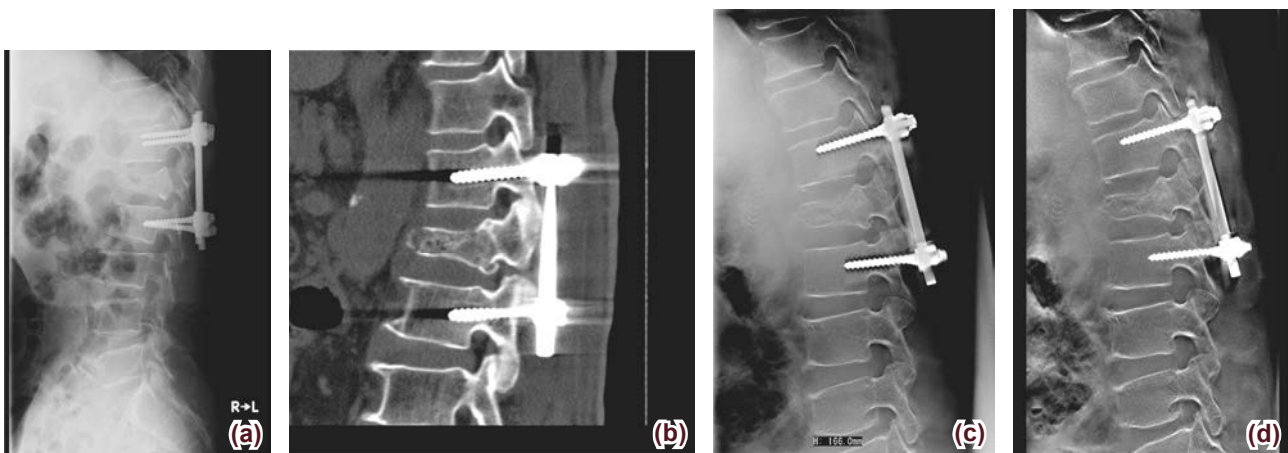
Even compared to a CT image (MPR image: Multi Planar Reconstruction image), with T-smart there are no metal artifacts and the image obtained has a high spatial resolution (Fig. 4). Before introducing the SONIALVISION safire series, our orthopedic physicians and medical X-ray technologists attended manufacturer presentations on use of the equipment and tried using the device to examine patients with metal implants.



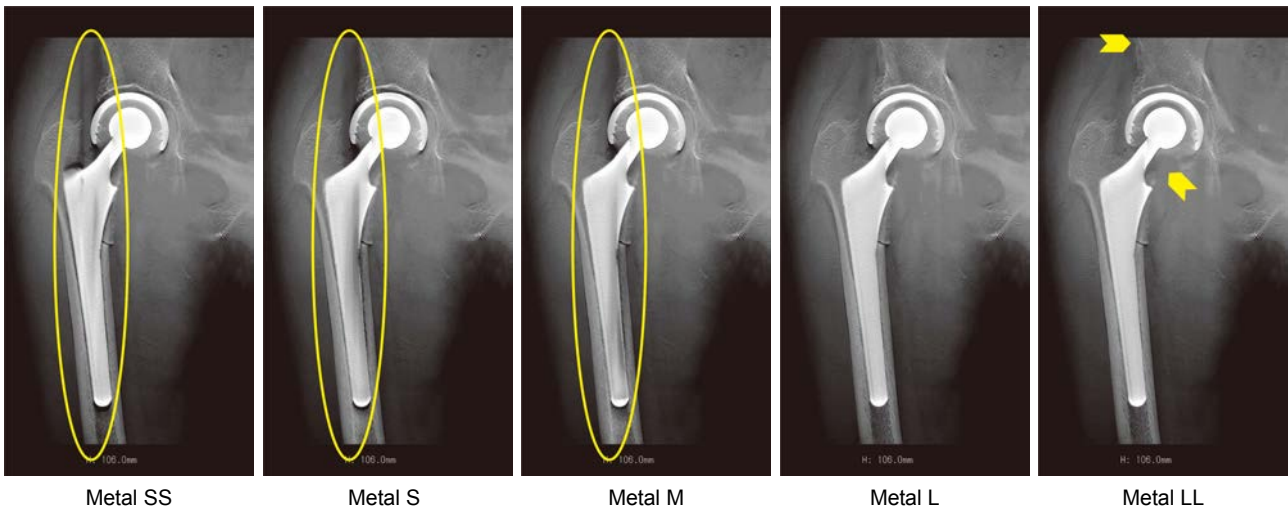
**Fig. 3** Comparison of Images Obtained by the FBP Method and T-smart  
With the FBP method bone evaluation is possible, but flowline artifacts can be further reduced using T-smart.

### 3. New Technology: T-smart

T-smart is an abbreviation of "Tomosynthesis – Shimadzu metal artifact reduction technology." T-smart separates the metal component, in the original image, from the rest of the image, creates tomosynthesis images by various methods of iterative approximation and then synthesizes the final image. T-smart comes with 10 different metal filters including: "Normal" when no metal is present at the imaging site; "Pin Wire (S, L)" for sites that contain only wires and a small number of stabilizing bolts; "Metal (SS, S, M, L, LL)" when the site includes plate stabilization, intramedullary rods, head prosthesis or artificial joints, and "Ext. Skeletal (S, L)" for metal in the form of external skeletal fixation. These metal filters must be used according to the quantity of metal implanted in the patient. Though the Metal (SS, S, M, L, LL) filters are frequently used, dependent on the size and amount of metal implanted, flowline artifacts will appear in the direction of imaging. Choosing a too large filter, however, will tend to remove the bone component of the image (Fig. 5). It is difficult to measure the amount of metal present before performing the reconstruction step. After using the system many times, it has become possible to guess the amount of metal some degree, but in the future, we intend to create a rough index to be used for estimating the amount of metal based on information obtained from plain radiography or a fluoroscopy image obtained just prior to tomosynthesis imaging.



**Fig. 4** Comparison of Artifacts in a CT Reconstructed Image and Tomosynthesis Images  
Artifacts are obvious in the CT image (b), are faintly apparent in the tomosynthesis image (c), and T-smart has reduced the artifacts around the screws (d).  
(a) Plain radiography image, (b) CT image, MPR sagittal section  
(c) Tomosynthesis, FBP method (Thickness +-2 %), (d) Tomosynthesis, T-smart (Metal M)



**Fig. 5** Differences in T-smart Metal Filters SS, S, M, L, and LL. Flowline artifacts in the HF (Head-Foot) direction appear with Metal SS, S and M. With Metal LL, there are no flowline artifacts but some of the bone components have been removed (arrows).

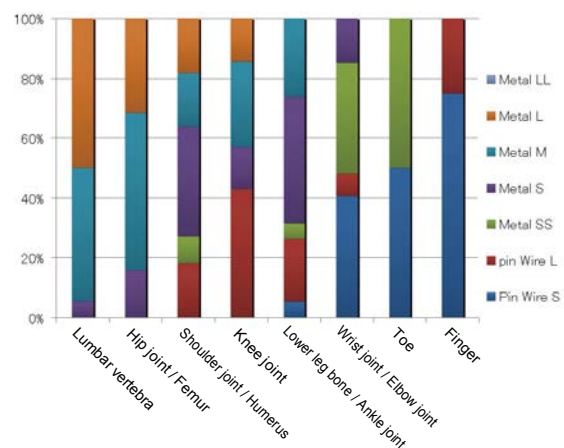
## 4. How Tomosynthesis (T-smart) Is Used at Our Hospital

Because there was only one R/F system at the former hospital, scheduling was implemented that divided use of the system into daily morning/afternoon slots to be allotted separately amongst the medical departments. Other than in emergencies, all exams were performed under this reservation system. As mentioned previously, with our transfer to a new hospital, the number of fluoroscopy systems has increased to two, and use of fluoroscopy system is now greatly diversified. System use is organized so tomography imaging can be always performed for orthopedic surgical practices in the mornings, and can also be ordered in the same manner as for plain radiography, which has been well received at the orthopedic surgery department.

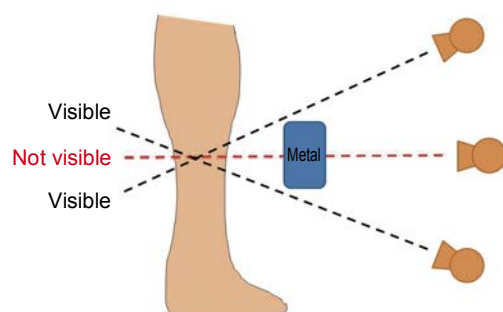
In the four-month period between January and April 2013, tomography imaging has been performed in 196 patients. Of these, T-smart images were obtained in 109 patients with metal implants. **Fig. 6** shows the proportional use of each T-smart metal filter according to imaging site. Metal M and Metal L filters were used most frequently in cases with a relatively large amount of metal such as a PLIF (Posterior Lumbar Interbody Fusion) on the lumbar vertebra, gamma nails or a head prosthesis on the hip joint, or an intramedullary rod in the femur. Pin Wire S and Pin Wire L filters were used most frequently in cases where wires and the like are placed distal to the knee joint or the elbow joint. When there is plate fixation of the ankle joint or wrist joint, Metal SS or Metal S filters tend to be used dependant on plate size. A particular metal filter may be designated for use according to a particular surgical procedure, but since the T-smart image is affected by the size of metal implant used,

this kind of method will affect the time later used for image reconstruction.

T-smart imaging can also be affected by the positional relationship between a fracture line and a metal implant, and its size. Depending on sites to be imaged, by moving the X-ray tube as shown in **Fig. 7** and employing additional processing with T-smart, to a limited extent at least, to depict the relationship between a fracture line and a metal implant. However, using this technique for confirming a positional relationship requires proper preparation.

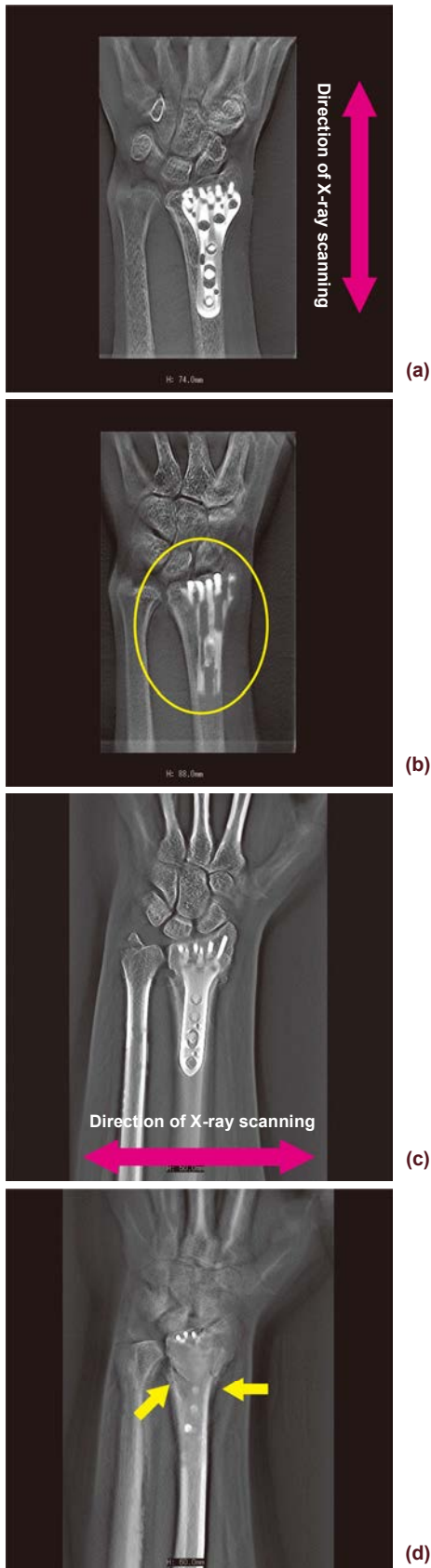


**Fig. 6** Proportional Use of T-smart Metal Filters at Each Imaging Site



**Fig. 7** Positional Relationship Between the X-Ray Tube and the Metal Implant

On imaging in the HF direction (a and b), the fracture line overlaps with the metal and is indistinct in the images, but when imaging was performed in the RL (Right-Left) direction (c and d), it was possible to render the fracture line.

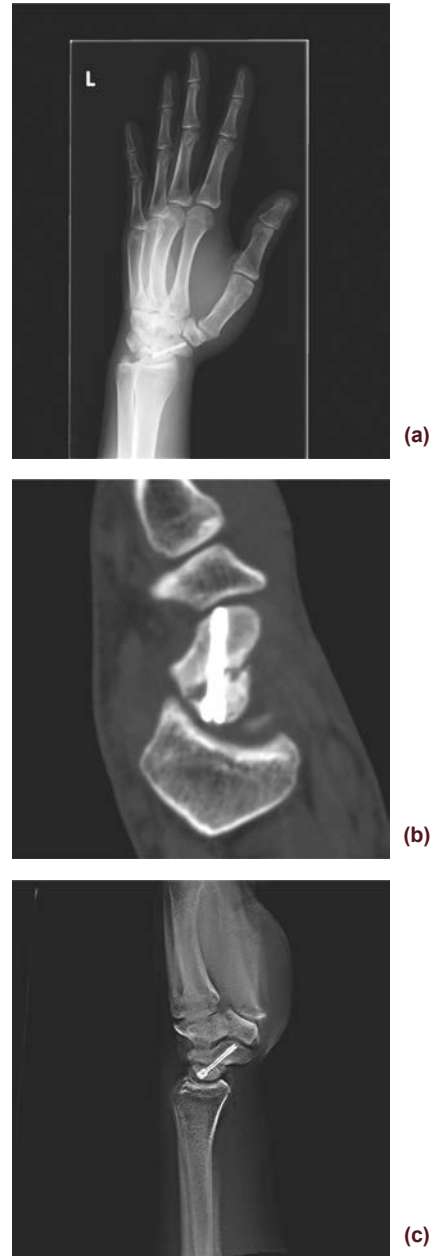


**Fig. 8** Different Directions of X-Ray Tube Travel Relative to the Metal Implant  
 (a) and (b) X-ray scanning in HF direction  
 (c) and (d) X-ray scanning in RL direction

## 5. Case Examples

### Case 1: Non-Union of Navicular Bone

Patient admitted for bone graft. After surgery, progress was observed by plain radiography image (a) and CT image (b), with tomosynthesis also utilized. With tomosynthesis (T-smart), the image was not affected by the metal present and the bone could be observed clearly (c).



(a) Plain radiography image  
 (b) CT reconstruction image, sagittal section  
 (c) Tomosynthesis, using T-smart (Pin Wire S)

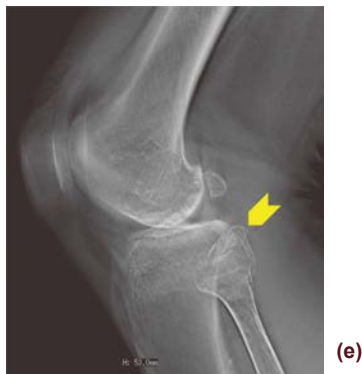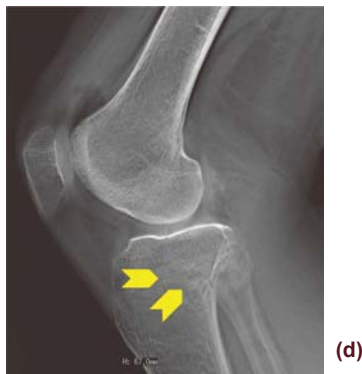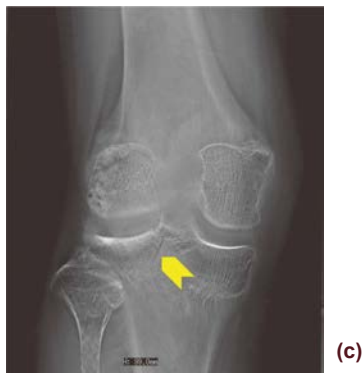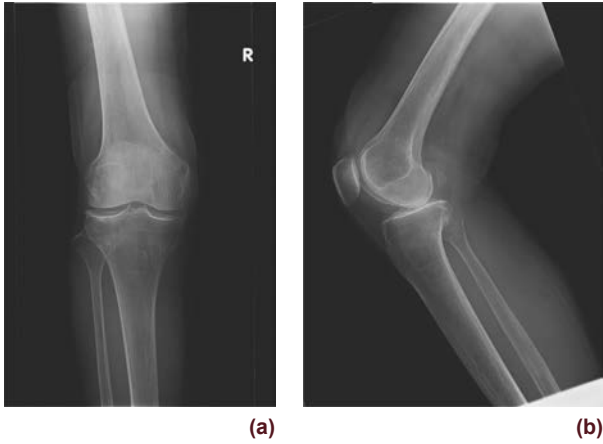### Case 2: Knee joint, tibial plateau fracture, fracture of fibula head

Bruising on left knee after traffic accident. No clear fracture on plain radiography image. Because blood and fat droplets were found in joint fluid, a fracture was suspected and tomography performed.



Although indistinct in plain radiography images (**a and b**), in tomosynthesis images (**c, d, and e**) a fracture line was visible along the outside of the tibia to the fibular head (arrows).

There was no substantial dislocation so surgery was not performed in favor of follow-up observation.

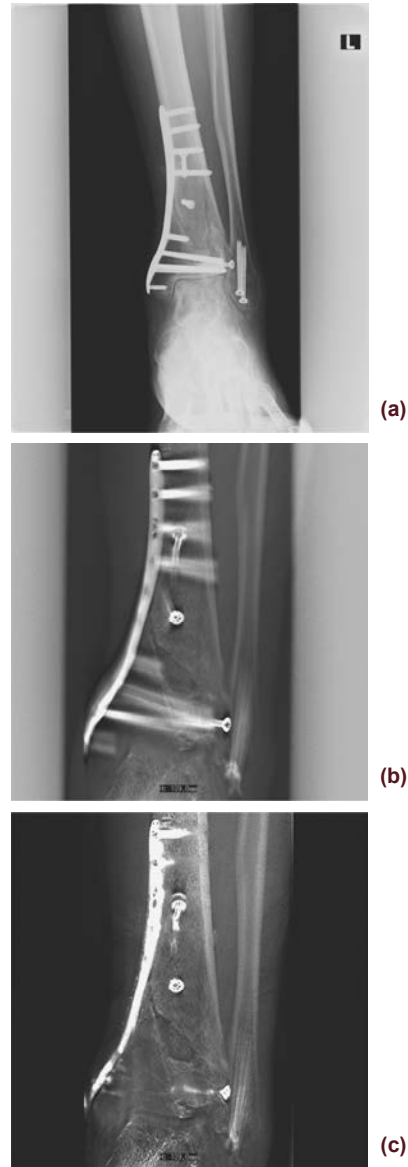

(a) Plain radiography image, frontal view  
 (b) Plain radiography image, lateral view  
 (c) Tomosynthesis FBP method, frontal view  
 (d) Tomosynthesis FBP method, lateral view  
 (e) Tomosynthesis FBP method, lateral view

### Case 3: Comminuted Fracture of Distal Tibia and Fibula

Injury sustained on fall from height. Above-mentioned fracture was found in plain radiography image (**a**) so open reduction and fixation was performed at a later date.

Fixation was achieved with a locking plate. In tomosynthesis images (**b and c**), progression of bone union can be clearly observed.



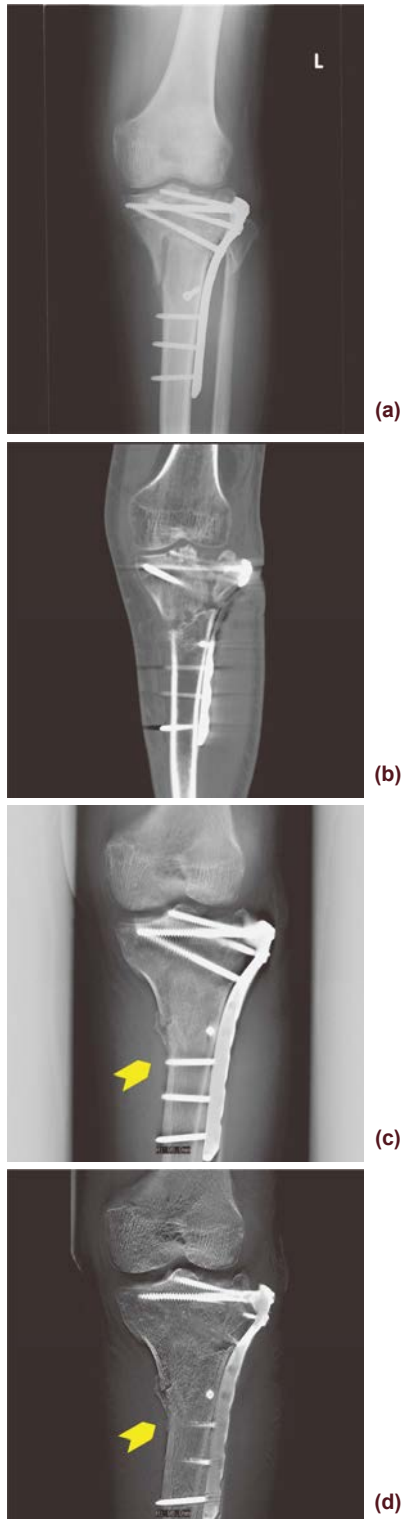(a) Plain radiography image, frontal view  
 (b) Tomosynthesis, FBP method (Thickness  $\pm 2\%$ )  
 (c) Tomosynthesis, T-smart (Metal S)

### Case 4: Knee joint, Comminuted Fracture of Proximal Tibia

Injury sustained in traffic accident. Above-mentioned fracture was confirmed in plain radiography image so open reduction and fixation was performed at a later date. Fixation was achieved with a locking plate. Follow-up was pursued with plain radiography image and CT, but CT was replaced with tomosynthesis in order to evaluate the case.

As plate size was differed from the patient in Case 3, T-smart Metal M filter was used.

Callus formation (arrows) appears clearer in tomosynthesis images **(c and d)** than in plain radiography image **(a)**, and trabecula is more clearly rendered in tomosynthesis images than in CT image **(b)**. The reconstruction image **(c)** obtained FBP-method tomosynthesis is sufficient for observation, though T-smart is able to further reduce artifacts **(d)** and is useful clinically as it provides a clearer evaluation.



**(a)** Plain radiography image, frontal view  
**(b)** CT reconstruction image, coronal section  
**(c)** Tomosynthesis, FBP method (Thickness ++2%)  
**(d)** Tomosynthesis, T-smart (Metal M)

## 6. Conclusion

Although we have only used tomosynthesis for four months since the system was introduced to the hospital, by using the T-smart with new tomographic image reconstruction algorithm, we have been able to further reduce artifacts beyond that of conventional tomosynthesis and obtain clear images of bone trabeculae at high resolutions useful in the evaluation of bones and joints.

Many imaging requests are received from the Extremity Trauma Center and orthopedic surgery department, and T-smart is utilized particularly in the follow-up of patients with metal implants after fracture surgery to observe rate of progression of callus formation and bone union. Tomosynthesis is also used for evaluation when a fracture line is indistinct in a plain radiography image and for evaluation of spinal compression fractures. The images obtained have been praised highly by our orthopedic surgeons.

Although tomosynthesis cannot be used to create the multi planar reconstruction images like CT, we intend to continue using tomosynthesis as a new examination tool in the field of orthopedic surgery in order to produce images that are useful for clinical care.

## References

- Kazutaka Sugimoto: Evaluation of TKA Loosening and Polyethylene Wear Using Iterative Reconstruction Tomosynthesis: 2.5D Imaging, *Medical Now*, No. 73, P12–P13, 2013
- Kazuyoshi Nishino: Metal Artifact Reduction of Tomosynthesis Images for Post-TKA Examination by Iterative Reconstruction Method, *Medical Now*, No. 73, P18–P19, 2013
- Kazuhiro Mori: A New Side Station for T-smart, *Medical Now*, No. 73, P20–P23, 2013
- Masanari Taniguchi: Utility of tomosynthesis in the orthopedic surgery at the Sumitomo hospital, *Rad Fan*, Vol. 9, No. 1, P37–P40, 2011
- Seitaro Endo: Using Tomosynthesis for the Evaluation of Bone and Metal Fixation After Total Knee Replacement, *Medical Now*, No. 73, P56–P57, 2013
- Kazuhiro Mori: The Principals of Supplying Iterative Approximation with Tomosynthesis and Clinical Applications, *Japanese Journal of Radiological Technology*, Vol. 69, No. 4, P457–P463, 2013